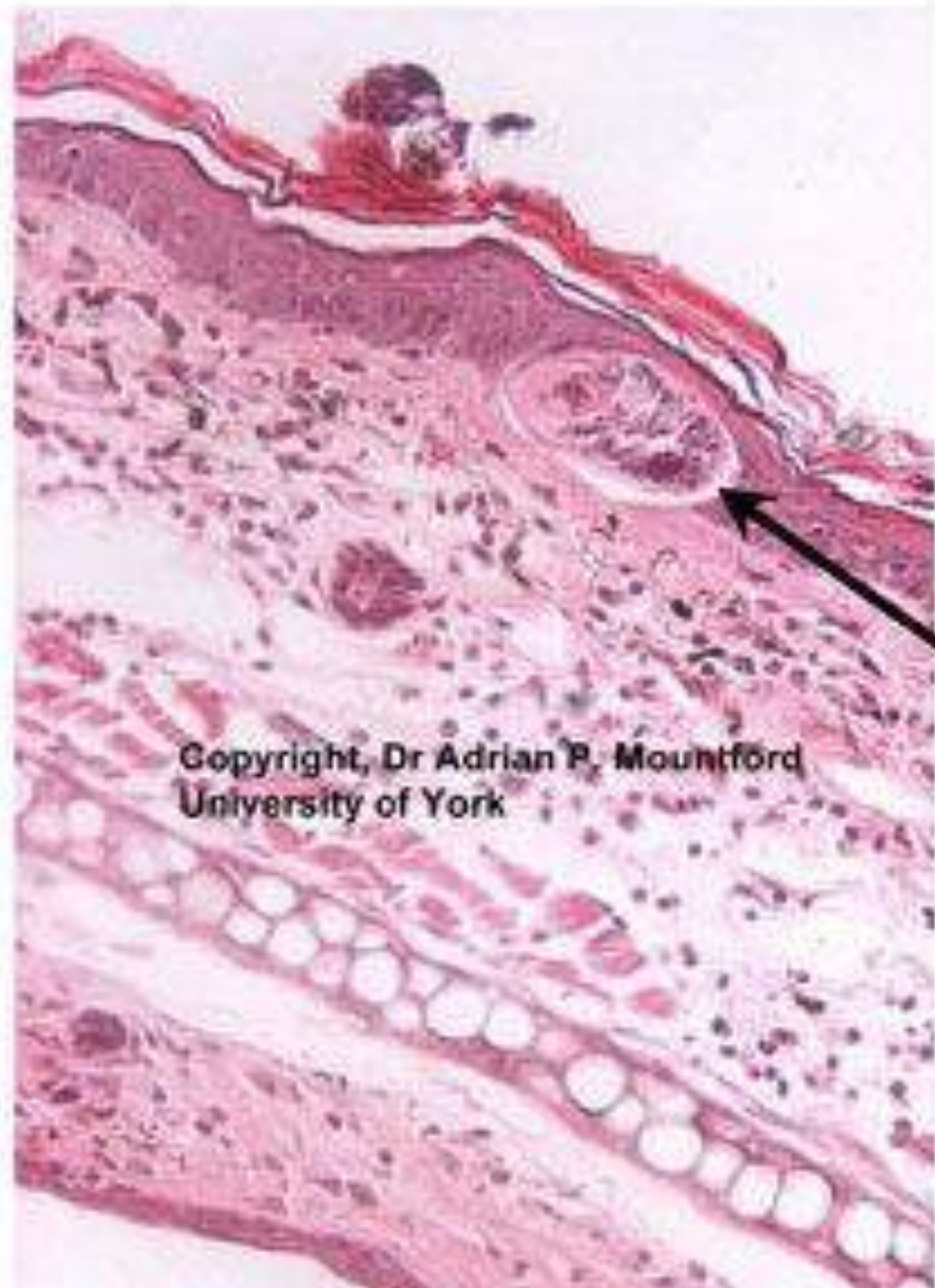

Stratum
corneum

Epidermis

Dermis

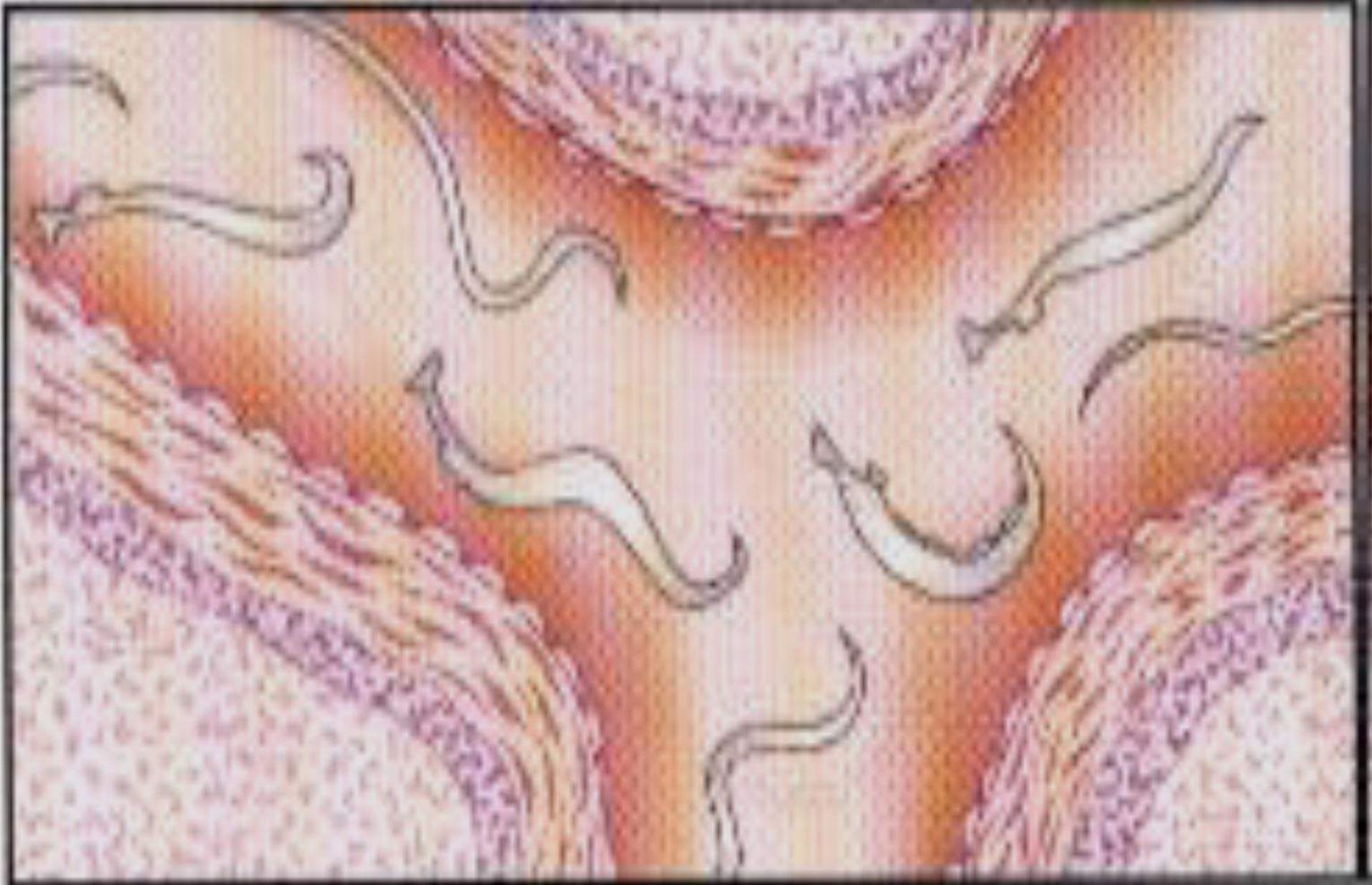
Cartilage



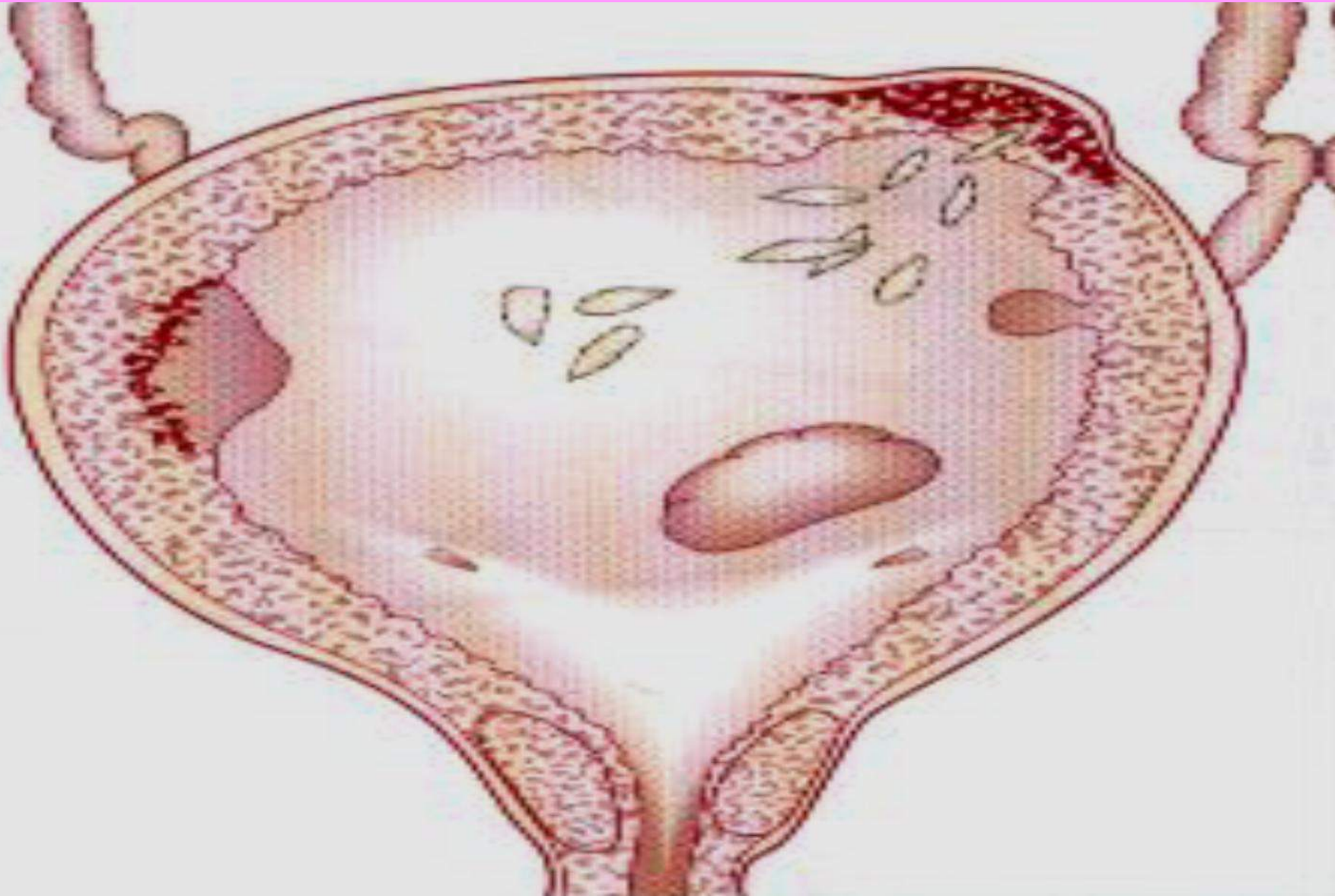
Copyright, Dr Adrian P. Mountford
University of York

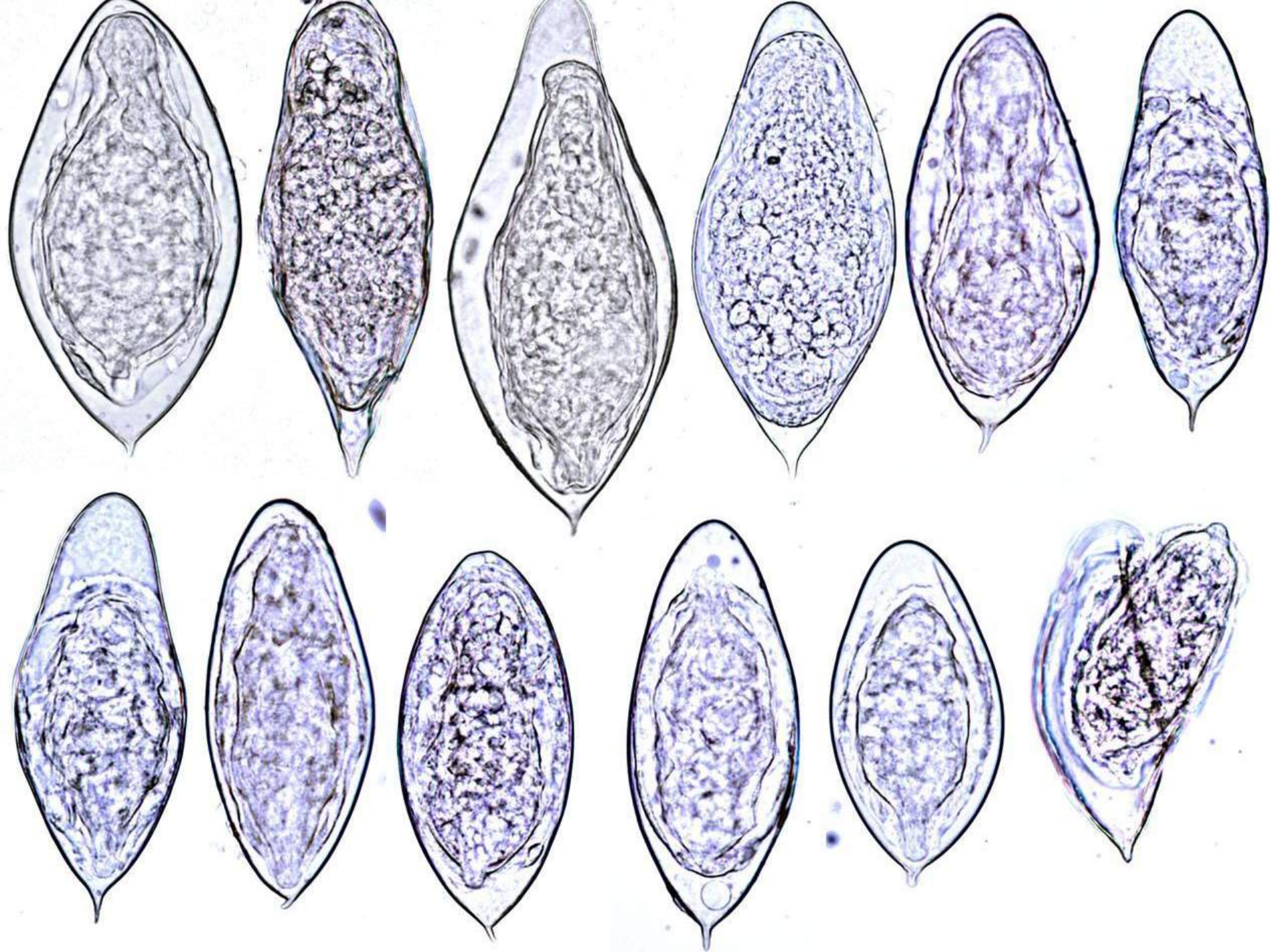
Schistosomulum in the
epidermis.

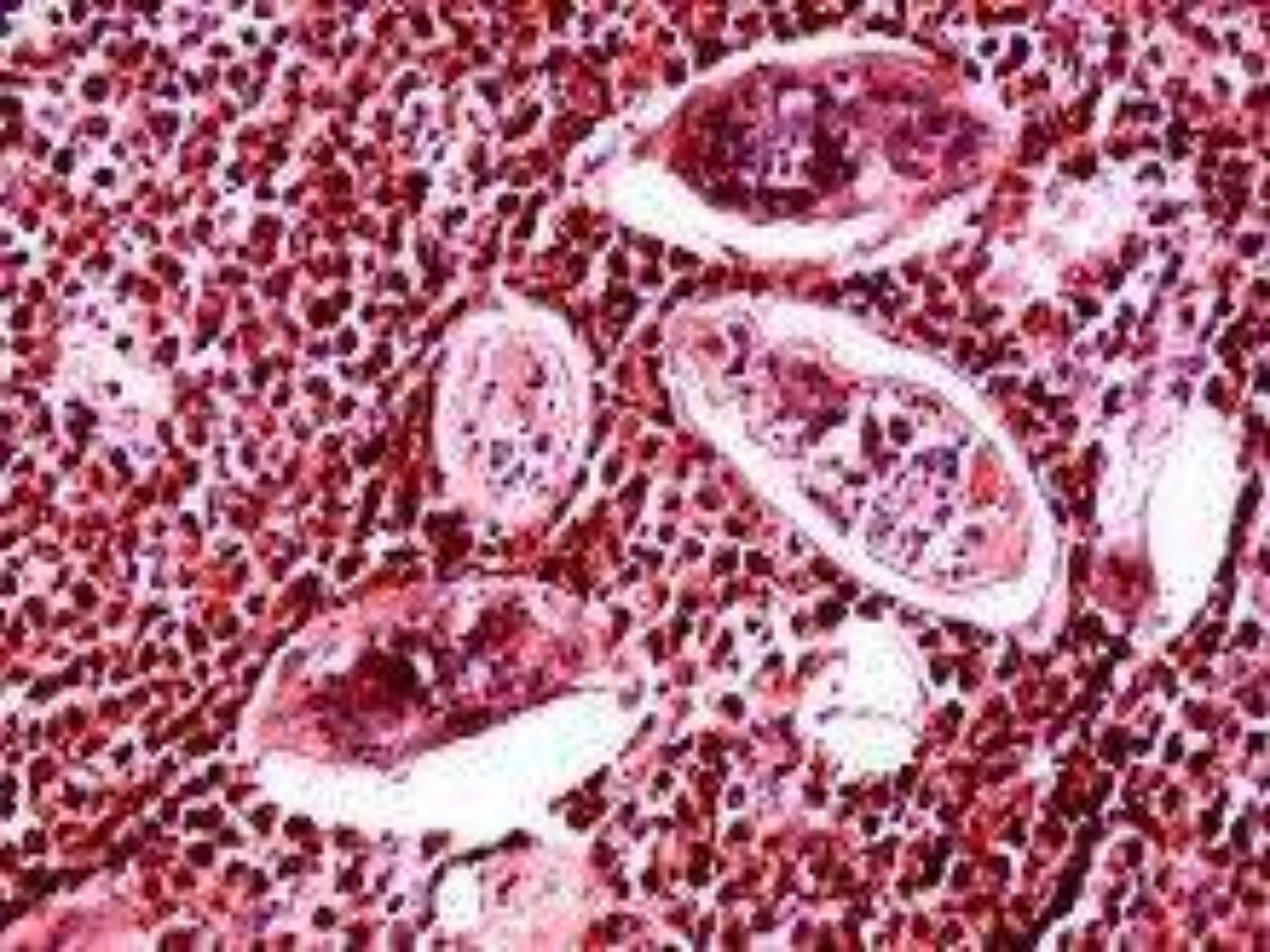
2- Migration and maturation of immature worms Katayama fever



3- Urinary Schistosomiasis

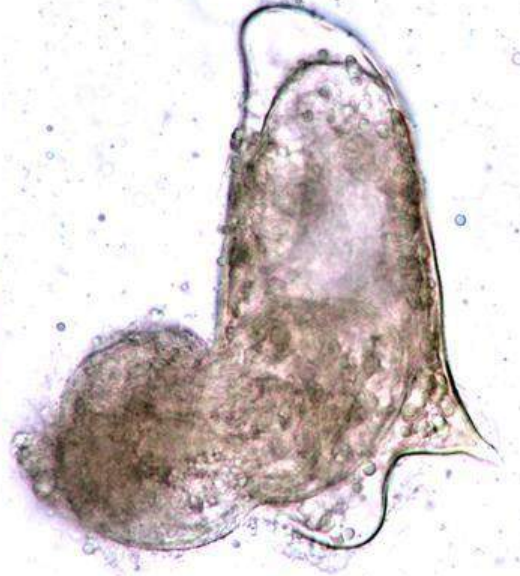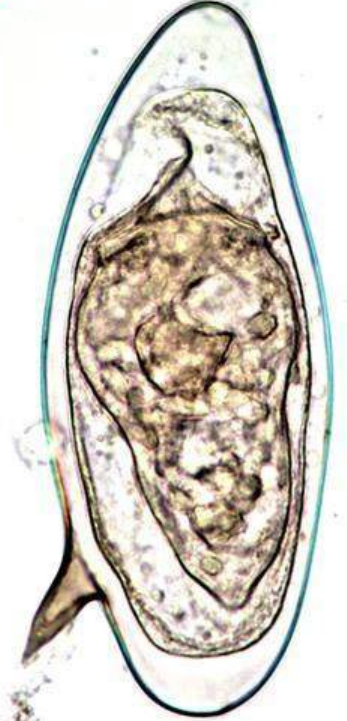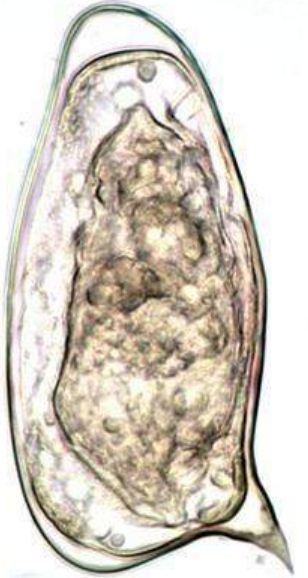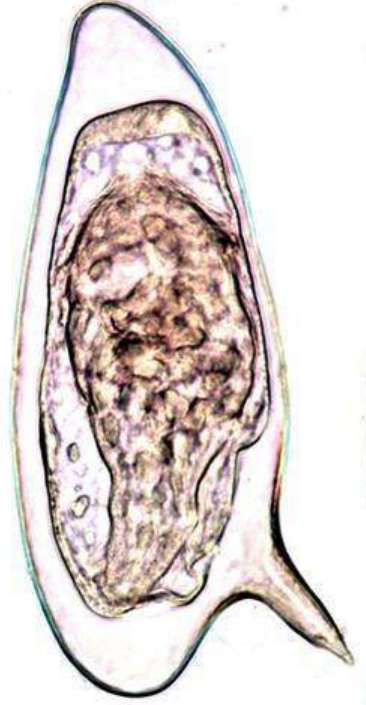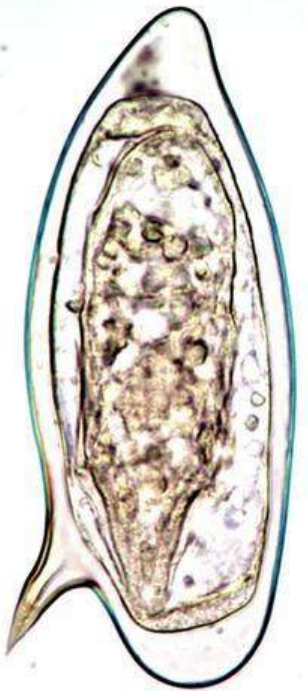
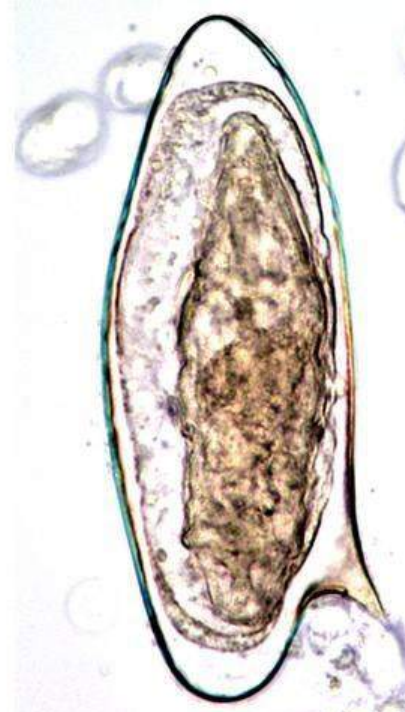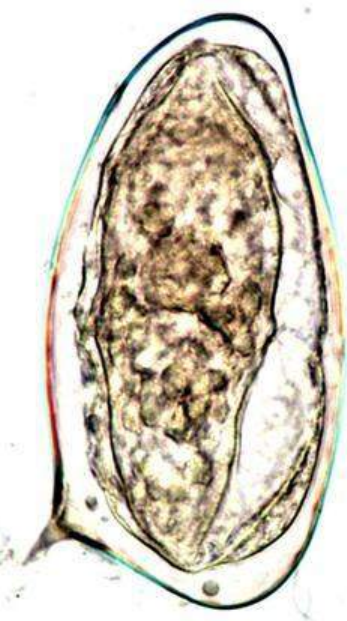
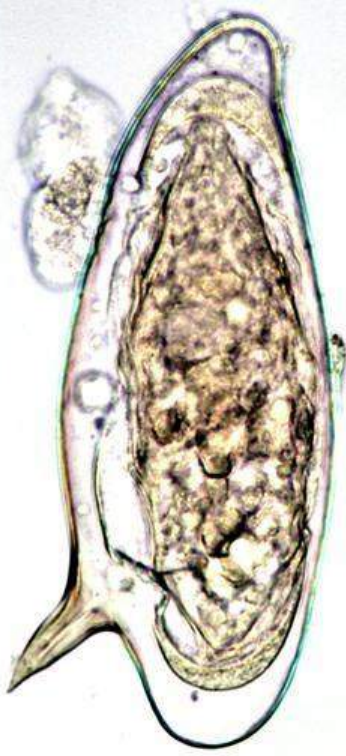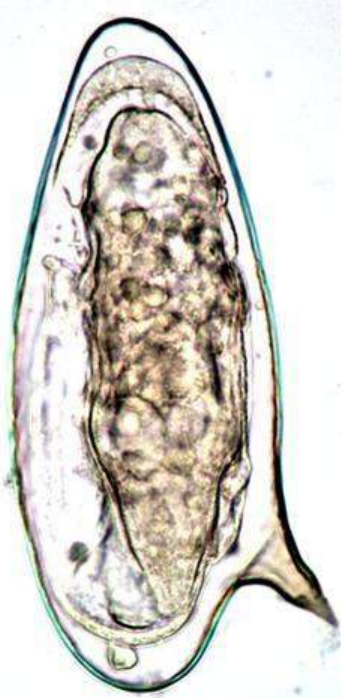


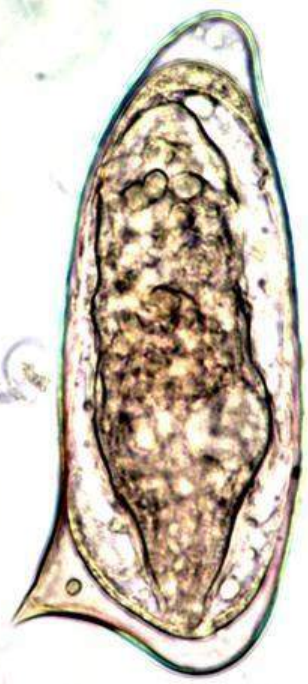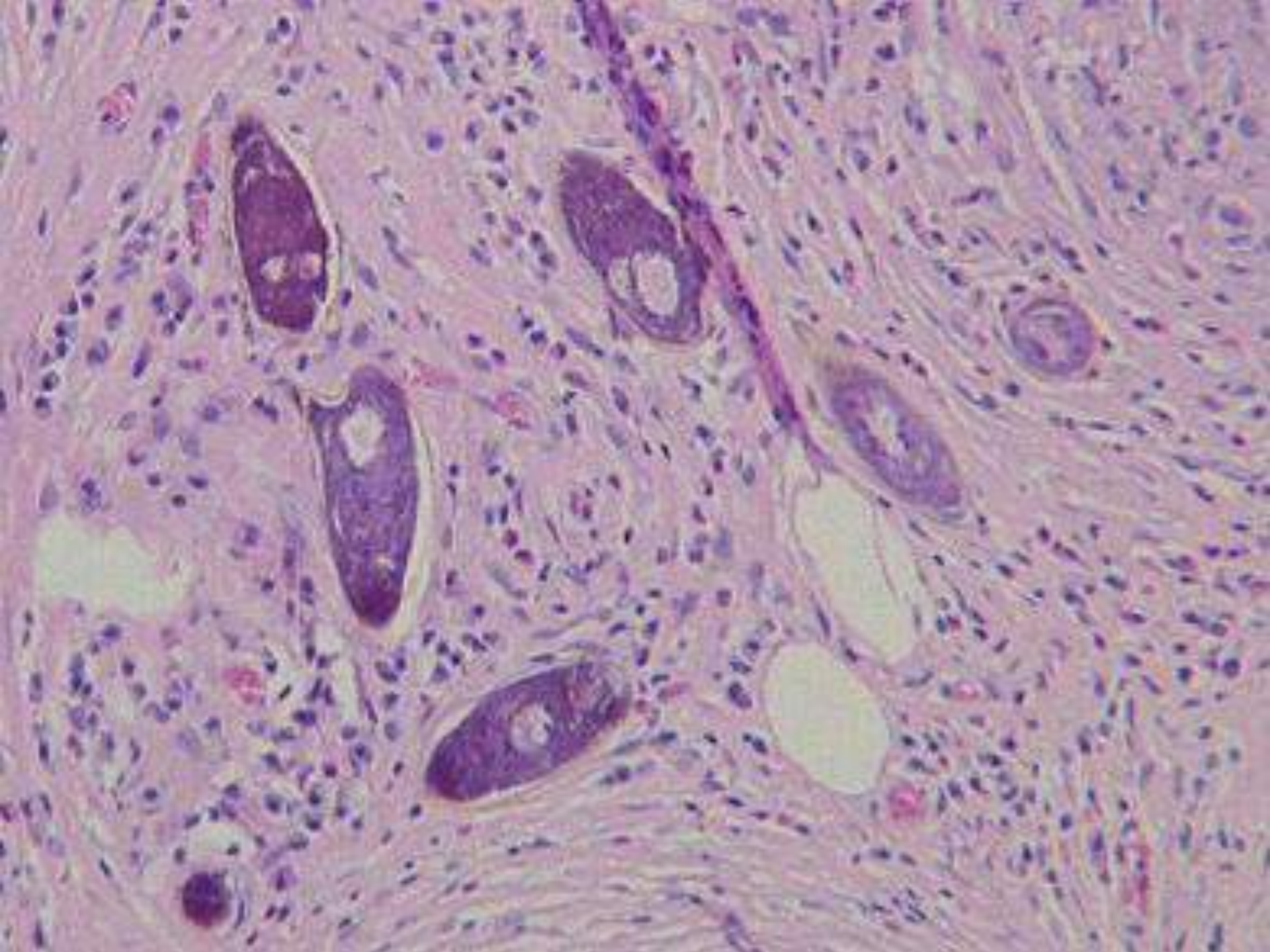




3- Intestinal Schistosomiasis







3- Oriental Schistosomiasis

