

# Cryptococcus

## Taxonomy

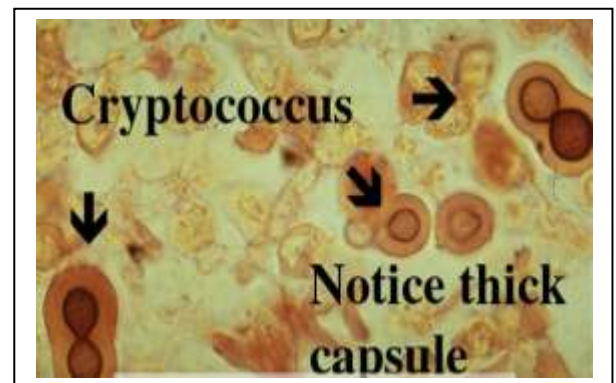
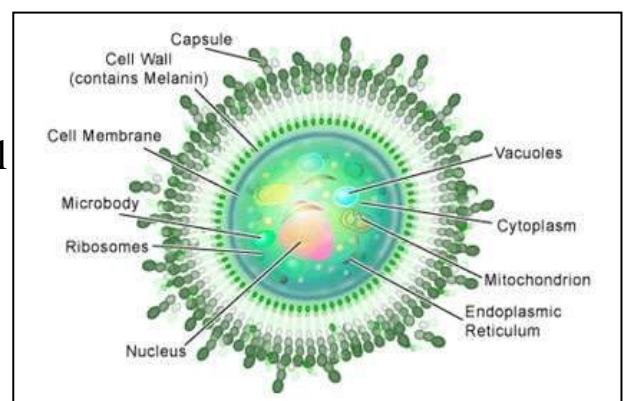
- Kingdom: Fungi
- Division :Basidiomycota
- Class: Basidiomycetes
- Order: **Filobasidiales**
- Genus: Filobasidiella
- (Cryptococcus)
- The genus Cryptococcus contains at least 39 species of yeast, but few are able to cause disease in humans.
- Most human infections are due to *C. neoformans*.
- Infection with the fungus Cryptococcus (either *C. neoformans* or *C. gattii*) is called cryptococcosis.
- Cryptococcosis is a global invasive mycosis associated with significant morbidity and mortality.
- Cryptococcosis usually affects the lungs or the central nervous system (the brain and spinal cord), but it can also affect other parts of the body.
- Brain infections due to the fungus Cryptococcus are called **cryptococcal meningitis**.
- **Cryptococcus neoformans** is a fungus that lives in the environment throughout the world.

## Cryptococcus neoformans

is dimorphic, existing in the asexual yeast form characterized by oval to spherical cells with a polysaccharide capsule, and in the sexual or perfect state characterized by the presence of basidiospores.

**C. neoformans** is readily cultured in the laboratory, producing mucoid colonies within 36–72 h, although growth is inhibited at 37 °C.

Colonies are white to cream in colour, but characteristic dark brown colonies are formed when grown on birdseed agar.



PATHOGEN	SEROTYPE	GEOGRAPHIC DISTRIBUTION	ENVIRONMENTAL ASSOCIATION	AFFECTED PATIENT GROUPS
<i>C. neoformans</i> var <i>grubii</i>	A	Worldwide	Birds, particularly pigeon excreta	HIV patients (98% of all isolates) Immunosuppressed patients Rarely immunocompetent
<i>C. neoformans</i> var <i>gattii</i>	B, C	Tropics and subtropics	Flowering eucalyptus trees	Immunocompetent patients
<i>C. neoformans</i> var <i>neoformans</i>	D	Worldwide	Birds, particularly pigeon excreta	Immunosuppressed patients Rarely immunocompetent
<i>C. neoformans</i> var <i>grubii</i> /var <i>neoformans</i> hybrid	AD	Not known	Not known	Rare clinical isolate Immunosuppressed

**C. neoformans** infections are not contagious. Humans and animals can get the infection after :

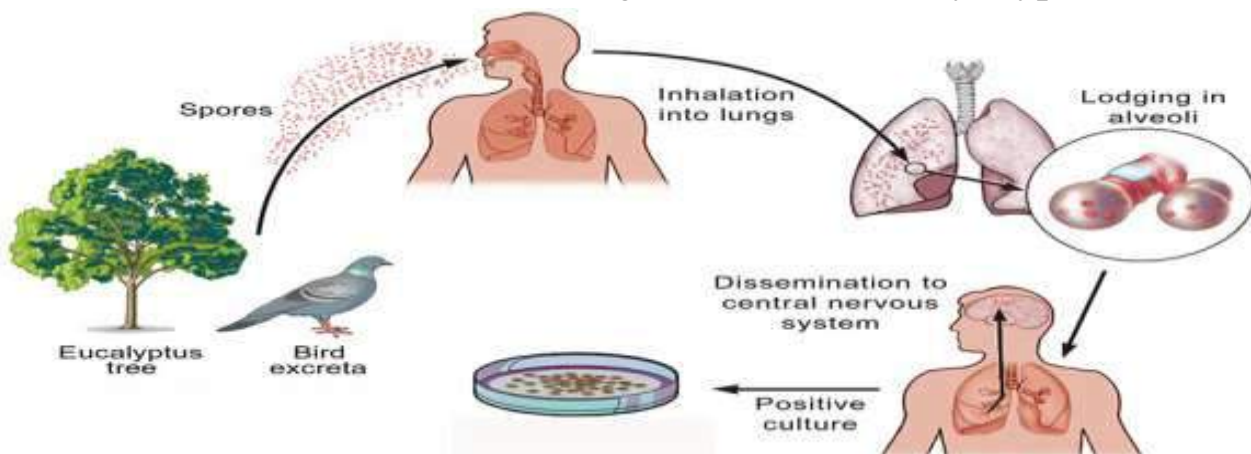
inhalation of the organism( basidiospores) from the environment.

no person to person transmission .

Meningitis is the most common manifestation of cryptococcal infection.

The lung is the second most common organ to develop clinical disease, usually pneumonia, which can occur in the immunocompetent

The skin is the third most common organ to be affected by cryptococcal infection



### Disseminated cryptococcosis:-

- CNS cryptococcosis.
- Cutaneous and mucocutaneous cryptococcosis .
- In osseous cryptococcosis cranial bones and vertebrae are commonly affected.
- Visceral cryptococcosis -most commonly heart, testis, prostate and eye.

## ❑ EPIDEMIOLOGY

Cryptococcosis is a rare infection in healthy human population

**C. neoformans** is a major cause of illness in people living with HIV/AIDS, with an estimated 1 million cases of cryptococcal meningitis occurring worldwide each year.

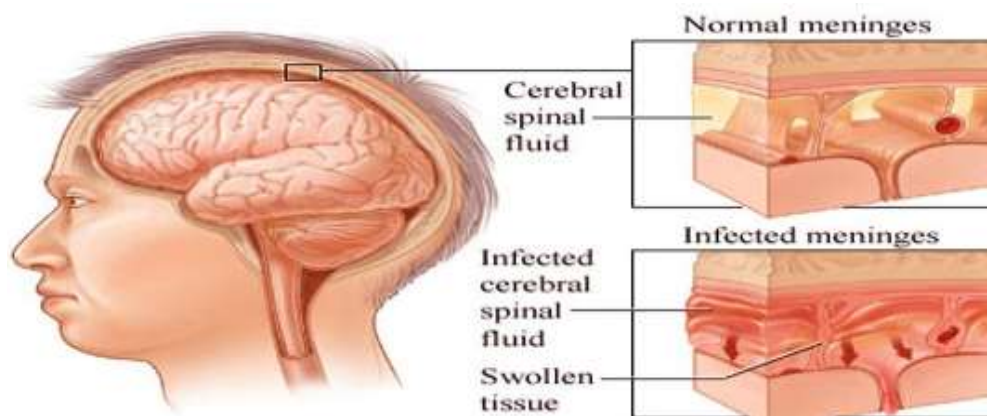
Most cases occur in the 20–50 years old age group.

## ❑ WHO ARE AT RISK?

Most cases of *C. neoformans* infection occur in people who have weakened immune systems, such as people who:

- Have advanced HIV/AIDS,
- Have had an organ transplant
- Sarcoidosis;
- Lymphoproliferative disorder;
- Hypogammaglobulinaemia;
- Systemic lupus erythematosus;
- Cirrhosis;
- Peritoneal dialysis
- Are taking corticosteroids, medications to treat RA, or other medications that weaken the immune system.

## CRYPTOCOCCAL MENINGITIS



## ❑ CLINICAL PRESENTATION:

In the **BRAIN** (cryptococcal meningitis)

Cryptococcal meningitis is an infection caused by the fungus *Cryptococcus* after it spreads from the lungs to the brain. The symptoms of cryptococcal meningitis include:

- Headache
- Fever
- Neck pain; neck rigidity
- Nausea and vomiting, lethargy, personality change, memory loss
- Sensitivity to light
- Confusion or changes in behavior
- The duration of symptoms before presentation is likely to be longer in non-AIDS patients, with a history of more than 2 weeks in only 25% of HIV positive patients.

- **Pulmonary cryptococcosis**

portal of entry

asymptomatic infection to life-threatening fungal pneumonia

acute pulmonary cryptococcosis

fever, productive **cough**, chest pain and weight loss

Radiographic presentations are varied - **single or multiple pulmonary nodules** – most common

Pulmonary infiltrates, pleural effusions, hilar lymphadenopathy, diffuse reticulonodular opacities, endobronchial lesion and findings mimicking pulmonary metastasis

Immunocompromised - alveolar and interstitial infiltrates tend to **be more frequent** and potentially **mimic pneumocystis pneumonia**

present with **CNS** rather than pulmonary symptoms

### **Central nervous system**

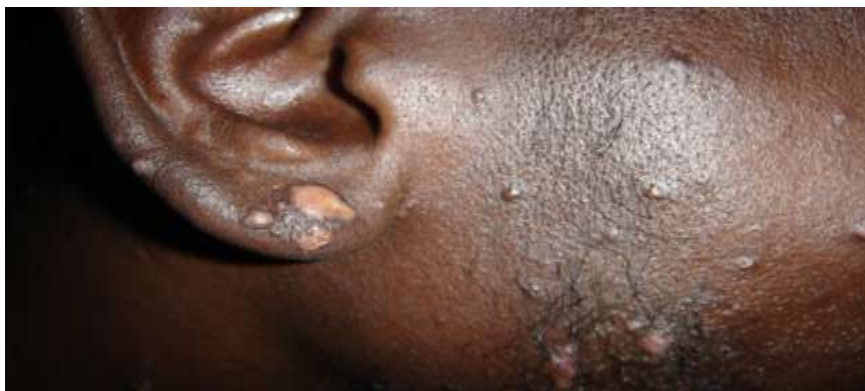acute, subacute or chronic meningitis, or **meningoencephalitis**

- headache, fever, cranial neuropathy, alteration of consciousness, lethargy, memory loss, meningeal irritation signs, and coma

- Meninges covering **basal ganglia and thalamus** involved
- cerebral lesions - most often **gelatinous areas of necrosis and cysts**

### **Skin**

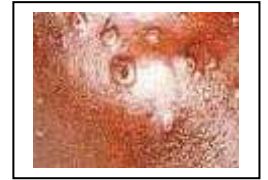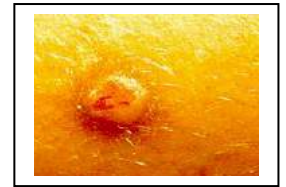- third most common clinical site
- Serotype D strains - propensity to cause cutaneous lesions.
- **primary** cutaneous infection from **direct inoculation** or a **secondary lesion** as part of **disseminated disease**





## Skin

- **Primary cutaneous cryptococcosis**
  - Solitary skin lesion - whitlow or phlegmon ,
  - history of skin injury
  - participation in outdoor activities
  - exposure to bird droppings, Eucalyptus trees
- **Secondary lesions**
  - **molluscum contagiosum-like lesion**
  - acneiform lesions, purpura, vesicles, nodules, abscesses, ulcers



## Prostate

- usually asymptomatic
- site for yeast sequestration after an occult or treated disseminated infection

## Other organs

- **Bone** – Osteolytic lesions with draining sinuses - disseminated infections
- **Eye** – Ocular involvement is common and classified in two categories
  - **Rapid visual loss** - 12 hours suggestive of optic neuritis due to **invasion of the yeasts** in the nerve, **usually reversible**
  - **Slow visual loss** - later in therapy and progresses over weeks to months, **due to increased intracerebral** pressure and can be halted by **shunts and optic nerve fenestration surgery**

## Laboratory diagnosis

- **Samples** include
  - CSF, sputum, BAL, lymph node aspirations, biopsy samples, blood, urine, and expressed prostatic secretion
- demonstration of the encapsulated budding round yeasts in a sterile body site by **India preparation or histopathology**
- **culture isolation** of the fungus from a sterile site
- detection of cryptococcal **capsular antigen**

## Laboratory diagnosis

● **India ink**, Modified India Ink (**with 2% chromium mercury**) and nigrosin stains - negative halo around the budding yeasts

**50%** sensitivity immunocompetent hosts

**> 80%** in immunocompromised hosts.

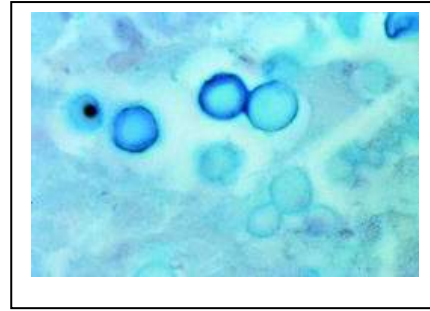
● **Mucicarmine and Alcian Blue** positive stains for the capsule

● **Mason Fontana stain** which stains melanin and

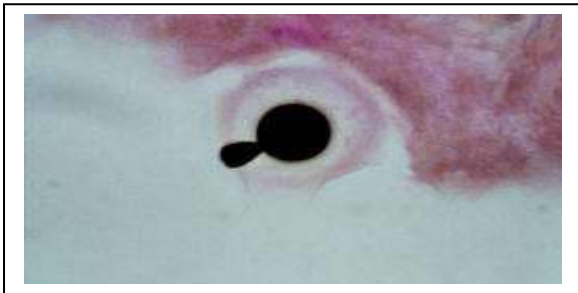
● **Gomori Methenamine Silver** staining – histopathology



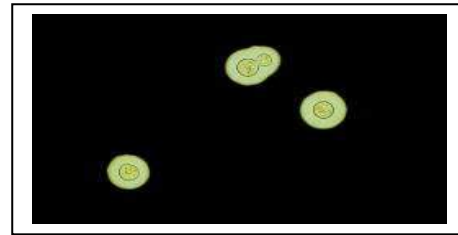
2% chromium mercury



Alcian blue stain



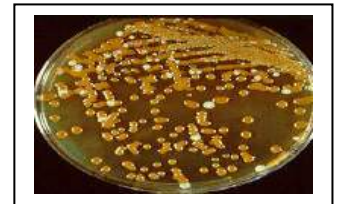Gomori's methenamine silver stain



India ink

- **Culture**

- CSF should be collected in large amounts (20ml) and centrifuged
  - Two Sabouraud Dextrose Agar (one each at 37 C and 25 C),
  - brain heart infusion agar and
  - Bird seed agar (or caffeic acid containing media)



- Colonies appear in 2-5 days - cream white to shiny in colour
- black on niger seed agar in 5 days.
- Confirmation - **urease test, positive inositol assimilation and negative nitrate assimilation test**

**Antigen detection in cryptococcosis**

- Antigen
  - Capsular polysaccharide
  - Protein antigen
- Methods
  - Pollysaccharide antigens
    - Latex agglutination
    - Elisa
    - Co-agglutination
  - Protein antigens
    - Elisa
    - Western blot

### **Antibody detection in cryptococcosis**

- cryptococcal antibodies **not helpful in diagnosing and deciding treatment** for cryptococcosis
- poor sensitivity and specificity performance
- **positive in the absence of overt disease**
- **Immunologically paralyzed status** of patients infected with HIV and those who are severely immunosuppressed

### **IMAGING:**

- CT brain scan is normal in 50% of patients with cryptococcal meningitis. The most common abnormal finding is hydrocephalus.
- Magnetic resonance imaging is more likely to demonstrate abnormalities than CT Scanning.

### **TREATMENT**

- Immune competent - Fluconazole, Itraconazole
- Immune Deficient – Amphotericin B, Flu cytosine
- **AIDS patients are not totally cured , Relapses are frequent with fatal outcome**
- Rapid resistance with Fluconazole.
- **Avoid contact with Birds**

### **PREVENTION**

- Fluconazole prophylaxis
- Active immunization- cryptococcal GXM-tetanus toxoid conjugate vaccine- in animal models, no human trials
- Monoclonal antibodies- would require repeated injections
- **Avoid high risk environments**